



Contents lists available at ScienceDirect

Journal of Pediatric Surgery

journal homepage: www.elsevier.com/locate/jped surg.org

Patient-reported physical and psychosocial significance of abdominal scarring in anorectal malformations

Louise Tofft^{a,*}, Stina Klasson^b, Martin Salö^a, Mette Hambraeus^a, Einar Arnbjörnsson^a, Pernilla Stenström^a^a Department of Pediatric Surgery, Skåne University Hospital Lund and Department of Clinical Sciences Lund, Pediatrics, Lund University, Lund, Sweden^b Department of Plastic Surgery, Skåne University Hospital Malmö and Department of Clinical Sciences Malmö, Plastic Surgery, Lund University, Lund, Sweden

ARTICLE INFO

Article history:

Received 27 August 2021

Revised 9 November 2021

Accepted 17 November 2021

Keywords:

Anorectal malformations

Postoperative scarring

Scar treatment

ABSTRACT

Background Abdominal scarring in patients with anorectal malformations (ARM) is a permanent visible sign of a chronic congenital condition. The study's aims were to assess the physical and psychosocial significance of abdominal scarring in ARM and to propose a scar treatment approach.

Methods A patient- and observer reported cross-sectional study of ARM patients with previous colostomies surgically treated 1997–2015 with minimum 4 years' follow-up after stoma closure. A maximum of 3 patient-selected scars per patient were evaluated by a) the Patient and Observer Scar Assessment Scale (POSAS; 11= no symptoms, 110=worst symptoms), b) pictorial scar treatment assessment by a plastic surgeon, c) questionnaire evaluation of the scarring's psychosocial aspects, bowel- and urinary function and quality of life. Descriptive statistics were presented in median (range) and percent (%), and Pearson's *r* was used to evaluate linear correlations. Ethical approval and written consents were obtained.

Results Twenty-seven patients (48% females) aged 12 (5–24) years old were included. Two (1–3) scars were evaluated per patient with a median POSAS score of 44 (15–78). Six patients (22%) reported scar pain, five (19%) scar pruritus and nine (33%) affected behavior, e.g. always wearing full-covered clothing in public places. Higher (worse) POSAS score and increasing age correlated ($r = 0.40, p = 0.04$). According to the plastic surgeon's assessment, 21 patients (78%) were suitable candidates for surgical scar treatment, among whom eight patients (30%) requested scar treatment.

Conclusions Postoperative abdominal scarring should require attention in clinical ARM follow-up programs including potential corrective plastic surgery for selected patients.

© 2021 The Author(s). Published by Elsevier Inc.

This is an open access article under the CC BY license (<http://creativecommons.org/licenses/by/4.0/>)

1. Introduction

Anorectal malformations (ARM), with an incidence of 1/5000 live births, cover a spectrum of heterogenous congenital conditions mainly affecting the hind gut and pelvic floor [1–3]. The malformations are often associated with urogenital-, gastrointestinal-, spinal- and heart malformations [4–6]. The genesis is unknown, but probably multifactorial [7,8].

Less complex ARM types are reconstructed with a primary posterior sagittal anorectoplasty (PSARP) [9]. More complex ARM types are reconstructed through a three-step procedure: a primary colostomy within the first days postpartum, followed by a delayed

PSARP under ostomy protection after some weeks/months, and finally stoma closure when the anorectal plasty has healed. A divided proximal sigmoidostomy with the two ostomy ends far apart has traditionally been recommended for patients with ARM, allowing a complete diversion of the feces and enough distal bowel length for the forthcoming reconstructive operation [10,11]. The classical procedure involves a partial abdominal paramedian incision not respecting skin Langer lines, which might negatively influence esthetically pleasing wound healing after colostomy closure [12]. If the ostomy ends are placed in the same transverse abdominal opening, this might result in less postoperative scarring after the colostomy is closed.

The morbidity of ARM patients during child- and adulthood can be substantial, including fecal incontinence, constipation, urinary incontinence, neurogenic bladder dysfunction, renal failure and sexual dysfunction. Long-term morbidity increases with ARM-type complexity and concomitant malformations [13,14]. Additional surgical interventions might therefore be needed in order to reduce anorectal and urogenital symptoms, including surgery for condi-

Abbreviations: ARM, anorectal malformations; BFS, Bowel Function Score; PedSQL, Pediatric Quality of Life Inventory; POSAS, Patient and Observer Scar Assessment Scale; PSARP, posterior sagittal anorectoplasty.

* Corresponding author at: Lasarettsgatan 48, S-221 85 Lund, Sweden.

E-mail address: louise.tofft@med.lu.se (L. Tofft).

tions associated with ARM, inevitably resulting in additional postoperative scarring.

Scars following surgical procedures in infancy and childhood are permanent and reported to grow with the child and adolescent [15,16]. In contrast to the numerous long-term outcome reports on bowel-, urinary- and sexual function in patients with ARM [13,14,17–23], physical and psychosocial significance of abdominal scarring has barely been acknowledged in this patient group. Our studies on outcome of adolescents born with, and surgically treated for, congenital malformations and tumors, indicated that postoperative scarring had a negative impact on some patients' physical and psychosocial well-being, severely affecting their everyday life [24–26]. Patients reported that their abdominal scarring constituted the only visible sign and was an unpleasant reminder of an otherwise hidden handicap due to a congenital chronic condition.

Scar-related physical symptoms such as pain and pruritus has been described previously in young burn victims and among children and adolescents with postoperative linear scarring [16,27,28] but never specifically for ARM patients. Current ARM follow-up programs do not address issues of postoperative scarring nor provide guidelines for potential scar treatment [11,29]. Therefore, increased knowledge about postoperative scarring and its physical and psychosocial significance for ARM patients is required urgently in order to provide adequate follow up.

The primary aim of this study was to assess the significance of postoperative abdominal scarring in children and adolescents born with ARM, reconstructed with a protective colostomy in infancy. The secondary aims were to identify any possible gender differences and to propose a scar treatment approach.

2. Methods

2.1. Study design

This was an observational cross-sectional study including ARM patients treated at a tertiary center of pediatric surgery between 1997 and 2015. Patients were identified through the hospital registers. Eligible study participants or their guardians were initially contacted by phone and presented with an oral study information, supplemented thereafter by written study information and a written formal study invitation by email.

The study was conducted in-person at the center of pediatric surgery with completion of questionnaires including clinical abdominal scar assessment by participants/guardians, a semi-structured follow-up interview based on the questions and answers in the questionnaires, clinical abdominal scar assessment by a pediatric surgeon, and photo documentation and measurements of scars. Afterwards, abdominal scarring was evaluated pictorially by a plastic surgeon who also received information on participant background and participant-reported scar symptoms. A maximum of three participant-selected abdominal scars, following any surgical procedures related to ARM or any concomitant malformation, were evaluated per participant. No financial compensation was offered to participants or their guardians.

2.2. Inclusion and exclusion criteria

Inclusion criteria were patients over 5 years of age born with ARM and reconstructed with a protective diverted colostomy in infancy. Follow-up time after stoma closure was at least 4 years. Exclusion criteria were cognitive disabilities including syndromes and any previous surgical scar treatment. During the study period some participants were excluded due to the institution's Covid-19-related patient contact restrictions.

2.3. Abdominal scar assessment

Participants having several abdominal scars were asked to personally select and assess a maximum of three abdominal scars following surgical procedures related to the anorectal- or any concomitant malformation. Participants were subsequently asked to complete questionnaires about scar symptoms, bowel function, urinary tract function and quality of life. Children under 13 years of age completed the questionnaire with assistance from their guardian. The answers were reviewed and clarified by participants and guardians in a semi-structured interview with researchers (authors LT and PS).

For abdominal scar assessment, the validated and comprehensive quantitative scar assessment score Patient and Observer Scar Assessment Scale (POSAS) [30,31] was used with a POSAS score of minimum 11 (no scar symptoms; just as normal skin) up to a maximum of 110 (severest scar symptoms, worst scar imaginable) per assessed scar. A cut-off of the POSAS score was set to 55 or higher for moderate to severe physical scar symptoms.

In the patient part of POSAS, participants scored six different categories of scar symptoms compared to their non-scarred skin: pain, pruritus, color, stiffness, thickness and irregularity, on a scale from 1 (no symptoms, as normal skin) to 10 (severest symptoms, very different to normal skin), thus with a minimum patient score of 6 (no symptoms) and a maximum of 60 (severest symptoms). Participants also answered additional questions regarding physical and psychosocial aspects of abdominal scarring, potential scar treatment requests and appropriate age for any potential scar treatment (Appendix 1).

A senior consultant in pediatric surgery with documented proficiency in plastic surgery (author PS) assessed each participant's abdominal scarring clinically and completed the observer part of POSAS, scoring five different categories of scar appearance compared to non-scarred skin: vascularization, pigmentation, thickness, relief and pliability, on a scale from 1 (as normal skin) to 10 (worst scar imaginable), thus with a minimum observer score of 5 (as normal skin) and a maximum of 50 (worst scar imaginable). Each participant-selected assessed scar was measured and photographed. Neither the observer nor the participant (or guardian) was allowed to take part in each other's score.

2.4. Bowel- and urinary tract function, and quality of life assessment

For bowel function assessment, the established instrument Bowel Function Score (BFS) [32] was used, with a minimum (worst) score of 1 and a maximum (best) score of 20, mapping bowel symptoms and management: e.g. constipation, fecal soiling and use of enemas. A BFS of 17 or lower was considered as impaired function [32]. The BFS was supplemented with additional questions regarding the bowel function's overall impact on everyday life (Appendix 2).

Urinary tract function was assessed by a questionnaire mapping different urinary tract symptoms and management: e.g. incontinence, urinary tract infections, use of intermittent catheterization and the urinary function's overall impact on everyday life (Appendix 3).

The validated and age adapted instrument Pediatric Quality of Life Inventory (PedsQL)TM [33] was used for participants under 19 years of age regarding overall physical and psychosocial functioning with a total of 21–23 questions (depending on age) generating a mean score from 0 (worst) to 100 (best). A score of 83 has previously been seen in healthy individuals and a score of 77 in chronically ill individuals [33].

2.5. Scar treatment assessment

For study purposes, the clinical situation when referring children or adolescents from the pediatric surgery department to the plastic surgery department for scar treatment assessment, was mirrored. The local clinical routine when patients request scar treatment is to send a written referral to the Department of Plastic Surgery including information on age, medical history, previous surgeries, previous and present stomas, scar symptoms, and obligatory scar photographs.

In this study a senior consultant in plastic surgery (author SK) conducted a pictorial scar assessment following a standardized form regarding possibility of scar treatment and improvement, potential surgical- and anesthesiologic methods and treatment timing (Appendix 4). The plastic surgeon had all patient data available, except information on gender and any scar treatment requests enabling an objective assessment.

2.6. Statistical analysis

Data analyses were performed using SPSS® (IBM® SPSS® Statistics, version 26, 2019). In group comparisons for dichotomous data, Fisher's exact test was used while Mann-Whitney *U* test was used for continuous parameters. Continuous data were not normally distributed and were therefore presented as median (min-max), and categoric data as absolute numbers and percentages, *n* (%). Pearson's correlation analysis was used for analyzing linear correlation between the highest (worst) POSAS-scored scar per participant, age, BFS and PedsQL™ score. A *p*-value of <0.05 was considered to be significant.

2.7. Ethics

Ethical approval was obtained by the national Ethics Review Authority in Sweden (DNR 2020–00,529). Written informed consents and publication consents were obtained by participants or minors' guardians.

3. Results

Twenty-seven eligible patients, 13 (48%) females and 14 (52%) males with a median age of 12 (5–24) years, participated in the study.

Seventy patients, 30 females (43%) and 40 males (57%) with a median age of 15 (5–30) years, were initially identified in hospital registers. Fourteen patients were excluded directly due to cognitive disabilities, syndromes or previous surgical scar treatment, leaving 56 patients eligible for study invitation. Fifteen patients did not respond to the study invitation, 12 patients declined participation and two patients were excluded later due to the institution's Covid-19-related restrictions. In total, 48% of eligible participants were included in the study (27/56).

3.1. Abdominal scar assessment

The median number of abdominal scars was 2 (1–8) per participant, and a median of 2 (1–3) scars were assessed per participant. Information on participants' ARM subtypes, previous and present ostomies, and assessed scars after ostomies and other surgical procedures are specified in Table 1. The median scar length of each assessed scar was 6 (1–20) cm.

Six participants (22%) reported recurrent scar pain and five participants (19%) recurrent scar pruritus. The median POSAS score of all assessed scars was 44 (15–78). The median POSAS score for the highest (worst) scored single scar was 47 (18–78). Scars after previous colostomies and associated laparotomies had the highest

Table 1

ARM subtypes, previous and present types of ostomies, and assessed scars after previous surgical procedures and ostomies.

	Females <i>n</i> = 13	Males <i>n</i> = 14
Subtypes of ARM		
Perineal fistula	0	3
Vestibular fistula	6	–
Cloaca	7	–
Recto-bulbar fistula	–	3
Recto-prostatic fistula	–	6
Recto-bladder neck fistula	–	1
No fistula	0	1
Previous ostomies		
Sigmoidostomy	11	14
Transversostomy	2	0
Nutritive gastrostomy	1	0
Nephrostomy	0	1
Suprapubic catheter	0	2
Present ostomies		
Appendicostomy for antegrade enemas	6	1
Nutritive jejunocatheter	1	0
Vesicostomy	2	0
Monti channel	0	1
Assessed scars*		
Sigmoidostomy	18	18
Transversostomy	2	0
Appendicostomy	1**	0
Laparotomy	5	2
Laparoscopy	1	0
Suprapubic catheter	0	2
Nephrostomy	0	1
Nutritive gastrostomy	1	0

Values presented as the absolute number.

* some procedures and ostomies left multiple scars per participant.

** scarring close to present appendicostomy; ARM: anorectal malformations.

POSAS scores. Ten participants (37%) were regarded as having moderate to severe scar symptoms with a POSAS score of 55 or higher for the highest scored scar. Higher POSAS score and increasing age correlated: Pearson's correlation $r = 0.40$, *p*-value 0.04 (Fig. 1). A selection of scar photographs is displayed in Figs. 2–4 representing a spectrum of visual outcomes.

Nine participants (33%) reported altered behavior, e.g. always wearing full-covering clothing or avoiding public swim facilities, due to their abdominal scarring. Twelve participants (44%) stated that the scars represented memories of past endeavors in a predominantly positive way, embodying a sense of pride in overcoming great challenges. Five participants (19%) regarded their scars with dismay and as sources of painful and unwanted memories. Four participants (15%) shared experiences of constant inquiries by other people about their scars and being subjected to rude comments and glares. Guardians of three participants stated that seeing their children's scars brought back painful memories of traumatizing hospital stays with an overwhelming fear of losing their newborn child.

Eight participants (30%), all 12 years old or older, five females (38% of females) and three males (21% of males), requested scar treatment: one (4%) due to scar pain, five (19%) for solely esthetic reasons and two (7%) for both physical and esthetic reasons. All of them requested scar treatment for their sigmoid- or transversostomy scars. The median POSAS score of the highest scored scar was higher among the eight participants requesting scar treatment compared to the other 19, but it did not differ significantly: 56 (35–76) vs. 38 (18–78) (*p*-value 0.12). All participants and guardians stated that the patient themselves should decide whether or not scar treatment should be undertaken, and they suggested that the appropriate age for this decision was from early teens and onwards. Participants and guardians also emphasized that this decision should only be taken after a thorough surgical consultation and the receiving of age-appropriate information.

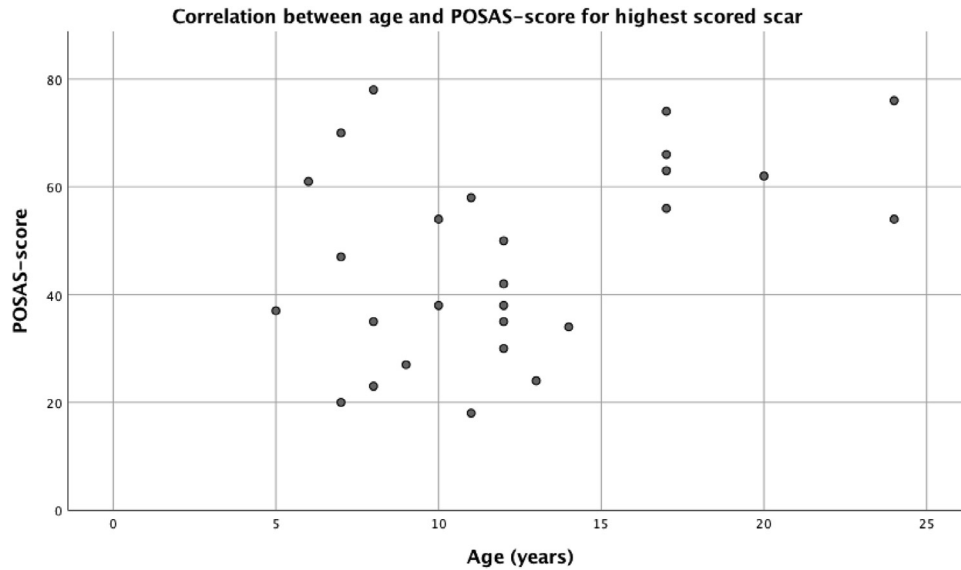


Fig. 1. Correlation between age and POSAS score for highest (worst) scored scar (11=as normal skin, 110=worst scar imaginable). Pearson correlation coefficient $r = 0.40$ (p-value 0.04).

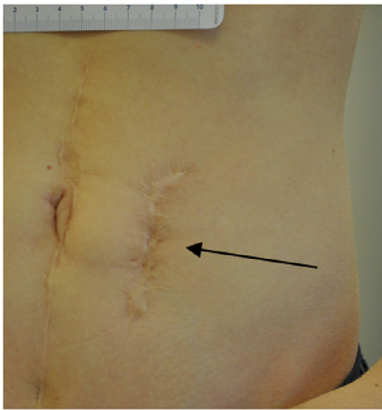


Fig. 2. A broad secondary-healed and partially depressed abdominal scar after a left paramedian incision with a former divided sigmoidostomy (arrow) in a male participant, here 16 years old, with POSAS score of 74.

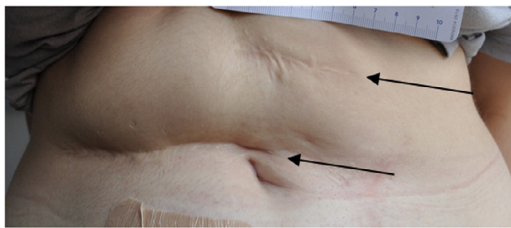


Fig. 3. Depressed and partially secondary-healed abdominal scars after an upper right transverse incision (lower arrow) and a former transversostomy (upper arrow) in a female participant, here 23 years old, with POSAS scores of 76 (lower arrow) and 74 (upper arrow).

3.2. Bowel- and urinary tract function and quality of life assessment

In the BFS, participants scored a median of 13 (8–20), and 24 participants (89%) had a lowered bowel function ($BFS \leq 17$). Twenty participants (74%) reported at least occasional fecal soiling and nine participants (33%) at least occasional larger fecal accidents. Nineteen participants (70%) used enemas regularly every week within their bowel management program.

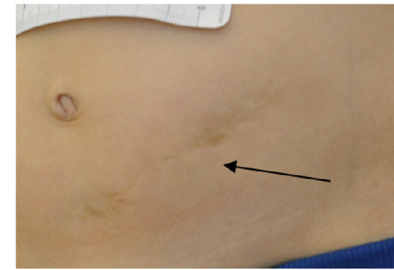


Fig. 4. A flat and thin abdominal scar after a lower left transverse incision with a former divided sigmoidostomy (arrow) in a male participant, here 8 years old, with POSAS score of 35.

Regarding urinary tract function, 17 participants (63%) reported at least occasional daytime urinary incontinence and 6 (22%) used intermittent urethral catheterization.

Twenty-five participants under the age of 19 years responded to the PedsQL™ questionnaire, scoring a median of 80 (52–99), of whom nine participants (36%) were regarded as having a reduced overall quality of life-score, compared to healthy individuals, with a PedsQL™ score ≤ 77 .

No statistically significant correlations were identified between each participant's highest POSAS-scored scar and BFS- ($r = 0.06$, p-value 0.78) or PedsQL™ score ($r = -0.12$, p-value 0.56). Furthermore, there were no statistically significant gender differences in POSAS-, BFS- and PedsQL™ scores or scar treatment requests (Table 2).

3.3. Scar treatment assessment

According to the plastic surgeon's pictorial assessment, 21 participants (78%) had abdominal scars technically suitable for surgical scar correction: under general anesthesia in 19 cases (90%) and under local anesthesia in two cases (10%). Surgical scar correction was suggested in all presumptive cases due to esthetic reasons because of broad secondary-healed scars and/or depressed scarring. In six of these cases, scar treatment was also offered due to scar pain but without any guaranteed post-surgical pain relief. In five presumptive cases (24%) the plastic surgeon requested co-surgery

Table 2

Gender comparisons regarding POSAS scores (11=best, 110=worst), BFS (1=worst, 20=best) and PedsQL™ scores (0=worst, 100=best), and scar treatment requests by participants.

	Femalesn = 13	Malesn = 14	p-value
POSAS score of highest (worst) scored scar	50 (18–78)	38 (20–74)	0.42*
BFS score	13 (9–20)	14 (8–20)	0.49*
PedsQL score	79 (52–96)	82 (52–99)	0.53*
Scar treatment request	5 (38)	8 (57)	0.45**

Values presented as the absolute number and percentage n (%), and as median (min–max).

* Mann-Whitney U test, two tailed.

** Fisher's exact test, two tailed; POSAS: Patient and Observer Scar Assessment Scale; BFS: Bowel Function Score; PedsQL™: Pediatric Quality of Life Inventory™

with a pediatric surgeon in case the bowel or bladder could interfere with the abdominal wall dissection. All eight participants who requested scar treatment were suitable for surgical scar correction according to the plastic surgeon's blinded assessment.

Surgical scar correction in children under the age of 7 years was not considered favorable by the plastic surgeon due to expected body growth and natural scar maturation. In addition, the plastic surgeon emphasized the importance of the patient's personal request and informed consent prior to any scar correction.

4. Discussion

According to this study, abdominal scarring in ARM patients seems to have physical and psychosocial significance requiring attention, regardless of gender. Postoperative scarring had a negative physical impact with recurrent scar pain and/or scar pruritus occurring in 29% of participants. Thirty-seven percent of participants were considered to have moderate to severe scar symptoms, and the severity of scar symptoms increased with participants' age. The psychosocial effects of postoperative scarring varied greatly between participants, with some participants reporting that they were proud of their scars while others reported negative feelings and social consequences. Thirty percent of participants requested scar treatment, a vast majority for esthetic reasons, of which all were suitable for corrective plastic surgery according to a pictorial assessment by a plastic surgeon.

The negative physical impact of postoperative scarring including scar pain and pruritus is a well-known phenomenon observed in previous studies among other patient groups [16,34], and this study confirms a similar impact in patients with ARM. Postoperative scarring caused a variety of psychosocial effects among participants in this study, which is in line with findings from previous studies [24,25,35]. For some participants, their abdominal scars were a visible sign of an otherwise hidden handicap that generated unwelcome questions and glares. In contrast, other participants declared that their visible scars made them feel proud, signaling overcoming past adversities.

The present study showed an interesting correlation between increasing age and severity of scar symptoms. As a result of the longitudinal follow-up design, this result might be attributed to a change in surgical technique over time. Our department has gradually shifted from paramedian stomas to lower, transverse incisions, which might contribute to a better esthetic outcome. Other possible explanations could be directly age-dependent, i.e. body maturation with more subcutaneous fat tissue and thus proneness to more depressed scarring and, with age, increasing body image awareness.

No correlation between scar symptom severity and lower overall quality of life score could be shown in this study. This could, speculatively, be a result of a too small a study sample size and

skewed data. It could also be that the assessment of quality of life with PedsQL was too general to identify the scars' possible impact on overall quality of life.

Results of the study revealed novel knowledge regarding ARM patients' requests for scar treatment, which should be included in ARM follow-up programs and most likely in the follow-up of other congenital conditions requiring surgery. One-third of participants requested scar treatment, mainly for esthetic reasons, and they were all considered to be suitable for corrective plastic surgery due to broad secondary-healed scars and/or depressed scars. This study indicated a need for a standardized cooperation between pediatric- and plastic surgeons to promote surgical safety and avoid iatrogenic intra-abdominal damage when correcting scars from former colostomies and laparotomies performed in infancy.

The indication for a colostomy in ARM patients should always be well founded. In our present study, all females born with vestibular fistulas underwent routine reconstruction through a three-step procedure with a colostomy according to international recommendations at that time. It has then been shown that females born with vestibular fistulas can be reconstructed successfully through a primary PSARP without a colostomy, thus avoiding any abdominal scarring [36,37]. Nowadays this is standard clinical practice in our department.

In addition, prevention of unesthetic scars [12,34] should be a priority for every surgeon by avoiding too wide an incision, bearing in mind that all scars grow with the child [15,16], and by choosing the most appropriate incision location, preferably following Langer lines. This might be difficult if choosing a classical divided proximal sigmoidostomy with the ostomy ends placed far apart. Placing the ostomy ends in the same transverse abdominal opening might be considered in order to reduce and esthetically improve postoperative scarring after the colostomy is closed. Furthermore, the surgeon should practice modern gold-standard incision closure techniques, including multiple layer abdominal wall closure, subcutaneous closure and intracutaneous resorbable sutures, avoiding external skin sutures with risk of dot scarring. Proper postoperative wound management to promote favorable surgical wound healing is also of the uttermost importance [12,38].

This study was strengthened by a broad patient inclusion from a national ARM center, constituting a wide spectrum of ages and malformation complexities, as well as a consistent study design with clinical scar assessment by participants and the same observer.

Conclusions were limited since 29/56 (52%) eligible patients declined participation or did not respond to the study invitation. This hampers statistical power and imposes a risk of selection bias, with a possibly skewed patient group. The low inclusion rate may be explained by a time-consuming study design and lack of financial compensation. The validity of the results might have been improved if body mass index (BMI) and a body image score had been included in the analysis. Furthermore, the study would have been strengthened if several plastic surgeons had performed the scar reviews.

In conclusion, both physical- and psychosocial scar morbidity should be addressed regardless of gender in ARM follow-up programs. In selected cases, referral for plastic surgical scar assessment and treatment should be considered, in cooperation between pediatric- and plastic surgery departments.

Financial support statement

This research was supported by the Southern Health Care Region Research Funding, Southern Region Health Care Committee, Sweden.

Declaration of interests

None.

Supplementary materials

Supplementary material associated with this article can be found, in the online version, at [doi:10.1016/j.jpedsurg.2021.11.022](https://doi.org/10.1016/j.jpedsurg.2021.11.022).

References

- [1] Cassina M, Fascetti Leon F, Ruol M, Chiarenza SF, Scirè G, Midrio P, et al. Prevalence and survival of patients with anorectal malformations: a population-based study. *J Pediatr Surg* 2019;54:1998–2003. doi:10.1016/j.jpedsurg.2019.03.004.
- [2] Herman RS, Teitelbaum DH. Anorectal Malformations. *Clin Perinatol* 2012;39:403–22. doi:10.1016/j.clp.2012.04.001.
- [3] Levitt MA, Peña A. Anorectal malformations. *Orphanet J Rare Dis* 2007;2:33. doi:10.1186/1750-1172-2-33.
- [4] Jonker JE, Liem ET, Elzenga NJ, Molenbuur B, Trzpis M, Broens PMA. Congenital Anorectal Malformation Severity Does Not Predict Severity of Congenital Heart Defects. *J Pediatr* 2016;179:150–3 e1. doi:10.1016/j.jpeds.2016.08.047.
- [5] Ratan SK, Rattan KN, Pandey RM, Mittal A, Magu S, Sodhi PK. Associated congenital anomalies in patients with anorectal malformations – A need for developing a uniform practical approach. *J Pediatr Surg* 2004;39:1706–11. doi:10.1016/j.jpedsurg.2004.07.019.
- [6] Cuschieri A. Anorectal anomalies associated with or as part of other anomalies. *Am J Med Genet* 2002;110:122–30. doi:10.1002/ajmg.10371.
- [7] Svenningsson A, Gunnarsdottir A, Wester T. Maternal risk factors and perinatal characteristics of anorectal malformations. *J Pediatr Surg* 2018;53:2183–8. doi:10.1016/j.jpedsurg.2018.04.021.
- [8] Wijers CHW, van Rooij IALM, Marcelis CLM, Brunner HG, de Blaauw I, Roeleveld N. Genetic and nongenetic etiology of nonsyndromic anorectal malformations: a systematic review. *Birth Defects Res Part C - Embryo Today Rev* 2014;102:382–400. doi:10.1002/bdrc.21068.
- [9] Peña A, Devries PA. Posterior sagittal anorectoplasty: important technical considerations and new applications. *J Pediatr Surg* 1982;17:796–811. doi:10.1016/S0022-3468(82)80448-X.
- [10] Morandi A, Ure B, Leva E, Lacher M. Survey on the management of anorectal malformations (ARM) in European pediatric surgical centers of excellence. *Pediatr Surg Int* 2015;31:543–50. doi:10.1007/s00383-015-3700-5.
- [11] Bischoff A, Levitt MA, Peña A. Update on the management of anorectal malformations. *Pediatr Surg Int* 2013;29:899–904. doi:10.1007/s00383-013-3355-z.
- [12] Lee Peng G, Kerolus JL. Management of Surgical Scars. *Facial Plast Surg Clin North Am* 2019;27:513–17. doi:10.1016/j.fsc.2019.07.013.
- [13] Danielson J, Karlbom U, Graf W, Wester T. Outcome in adults with anorectal malformations in relation to modern classification – Which patients do we need to follow beyond childhood? *J Pediatr Surg* 2017;52:463–8. doi:10.1016/j.jpedsurg.2016.10.051.
- [14] Rigueros Springford L, Connor MJ, Jones K, Kapetanakis VV, Giuliani S. Prevalence of Active Long-term Problems in Patients with Anorectal Malformations: a Systematic Review. *Dis Colon Rectum* 2016;59:570–80. doi:10.1097/DCR.0000000000000576.
- [15] Wang MK, Li Y, Selekman RE, Gaither T, Arnhyim A, Baskin LS. Scar acceptance after pediatric urologic surgery. *J Pediatr Urol* 2018;14 175.e1-175.e6. doi:10.1016/j.jpuro.2017.11.018.
- [16] Krakowski AC, Totri CR, Donelan MB, Shumaker PR. Scar management in the pediatric and adolescent populations. *Pediatrics* 2016;137:e20142065. doi:10.1542/peds.2014-2065.
- [17] Vilanova-Sanchez A, Reck CA, McCracken KA, Lane VA, Gasior AC, Wood RJ, et al. Gynecologic anatomic abnormalities following anorectal malformations repair. *J Pediatr Surg* 2018;53:698–703. doi:10.1016/j.jpedsurg.2017.07.012.
- [18] Kyrklund K, Pakarinen MP, Rintala RJ. Long-term bowel function, quality of life and sexual function in patients with anorectal malformations treated during the PSARP era. *Semin Pediatr Surg* 2017;26:336–42. doi:10.1053/j.sempedsurg.2017.09.010.
- [19] Kyrklund K, Taskinen S, Rintala RJ, Pakarinen MP. Sexual Function, Fertility and Quality of Life after Modern Treatment of Anorectal Malformations. *J Urol* 2016;196:1741–6. doi:10.1016/j.juro.2016.08.079.
- [20] Rintala RJ. Congenital cloaca: long-term follow-up results with emphasis on outcomes beyond childhood. *Semin Pediatr Surg* 2016;25:112–16. doi:10.1053/j.sempedsurg.2015.11.011.
- [21] van den Hondel D, Sloots CEJ, Bolt JM, Wijnen RMH, de Blaauw I, Ijsselstijn H. Psychosexual Well-Being after Childhood Surgery for Anorectal Malformation or Hirschsprung's Disease. *J Sex Med* 2015;12:1616–25. doi:10.1111/jsm.12886.
- [22] Stenström P, Clementson Kockum C, Katsianikou Benér D, Ivarsson C, Arnbjörnsson E. Adolescents with anorectal malformation: physical outcome, sexual health and quality of life. *Int J Adolesc Med Health* 2014;26:49–59. doi:10.1515/ijamh-2012-0111.
- [23] Grano C, Bucci S, Aminoff D, Lucidi F, Violani C. Feelings of depression in people with arm: the role of critical incidents and perceived difficulties in close and sexual relationships. *Pediatr Surg Int* 2014;30:823–8. doi:10.1007/s00383-014-3532-8.
- [24] Hoel AT, Tofft L, Björnland K, Gjone H, Teig CJ, Øresland T, et al. Reaching adulthood with Hirschsprung's disease: patient experiences and recommendations for transitional care. *J Pediatr Surg* 2021;56:257–62. doi:10.1016/j.jpedsurg.2020.05.015.
- [25] Tofft L, Hoel AT, Håkansson C, Zawadzki A, Gjone H, Øresland T, et al. Key components of successful transition for adolescents born with anorectal malformations—a Nordic focus group study. *Int J Adolesc Med Health* 2020 20200052. doi:10.1515/ijamh-2020-0052.
- [26] Hambraeus M, Hagander L, Arnbjörnsson E, Börjesson A, Stenström P. Health-related quality of life and scar satisfaction in a cohort of children operated on for sacrococcygeal teratoma. *Health Qual Life Outcomes* 2020;18:1–7. doi:10.1186/s12955-020-01350-y.
- [27] Lawrence JW, Mason ST, Schomer K, Klein MB. Epidemiology and impact of scarring after burn injury: a systematic review of the literature. *J Burn Care Res* 2012;33:136–46. doi:10.1097/BCR.0b013e3182374452.
- [28] Örtqvist L, Almström M, Öjmyr-Joelsson M, Wigander H, Währner A, Wester T. Cosmetic and functional outcome after stoma site skin closure in children. *Pediatr Surg Int* 2011;27:1123–6. doi:10.1007/s00383-011-2933-1.
- [29] Giuliani S, Grano C, Aminoff D, Schwarzer N, Van De Vorle M, Cretolle C, et al. Transition of care in patients with anorectal malformations: consensus by the ARM-net consortium. *J Pediatr Surg* 2017;52:1866–72. doi:10.1016/j.jpedsurg.2017.06.008.
- [30] Van De Kar AL, Corion LUM, Smeulders MJC, Draaijers LJ, Van Der Horst CMAM, Van Zuijlen PPM. Reliable and feasible evaluation of linear scars by the patient and observer scar assessment scale. *Plast Reconstr Surg* 2005;116:514–22. doi:10.1097/01.prs.0000172982.43599.d6.
- [31] Draaijers LJ, Tempelman FRH, Botman YAM, Tuinebreijer WE, Middelkoop E, Kreis RW, et al. The Patient and Observer Scar Assessment Scale: a reliable and feasible tool for scar evaluation. *Plast Reconstr Surg* 2004;113:1960–5. doi:10.1097/01.PRS.0000122207.28773.56.
- [32] Kyrklund K, Koivusalo A, Rintala RJ PM. Evaluation of bowel function and fecal continence in 594 Finnish individuals aged 4 to 26 years. *Dis Colon Rectum* 2012;55:671–6. doi:10.1097/DCR.0b013e31824c77e4.
- [33] Varni JW, Seid M, Kurtin PS. *PedsQL™ 4.0: reliability and Validity of the Pediatric Quality of Life Inventory™ Version 4.0 Generic Core Scales in Healthy and Patient Populations*. *Med Care* 2001;39:800–12. doi:10.1097/00005650-200108000-00006.
- [34] Walmsley GG, Maan ZN, Wong VW, Duscher D, Hu MS, Zielins ER, et al. Scarless wound healing: chasing the holy grail. *Plast Reconstr Surg* 2015;135:907–17. doi:10.1097/PRS.0000000000000972.
- [35] Kohta M, Nishigaki C. Internet-based survey of the perceptions of surgical scars of Japanese patients. *Scars, Burn Heal* 2020;6:205951312092851. doi:10.1177/2059513120928515.
- [36] Short SS, Bucher BT, Barnhart DC, Van Der Watt N, Zobell S, Allen A, et al. Single-stage repair of rectoperineal and rectovestibular fistulae can be safely delayed beyond the neonatal period. *J Pediatr Surg* 2018;53:2174–7. doi:10.1016/j.jpedsurg.2018.02.048.
- [37] Kumar B, Kandpal DK, Sharma SB, Agrawal LD, Jhamariya VN. Single-stage repair of vestibular and perineal fistulae without colostomy. *J Pediatr Surg* 2008;43:1848–52. doi:10.1016/j.jpedsurg.2008.03.047.
- [38] Monstrey S, Middelkoop E, Vranckx JJ, Bassetto F, Ziegler UE, Meaume S, et al. Updated Scar Management Practical Guidelines: non-invasive and invasive measures. *J Plast Reconstr Aesthetic Surg* 2014;67:1017–25. doi:10.1016/j.bjps.2014.04.011.